

DW Dental History Survey

Data Collection Period

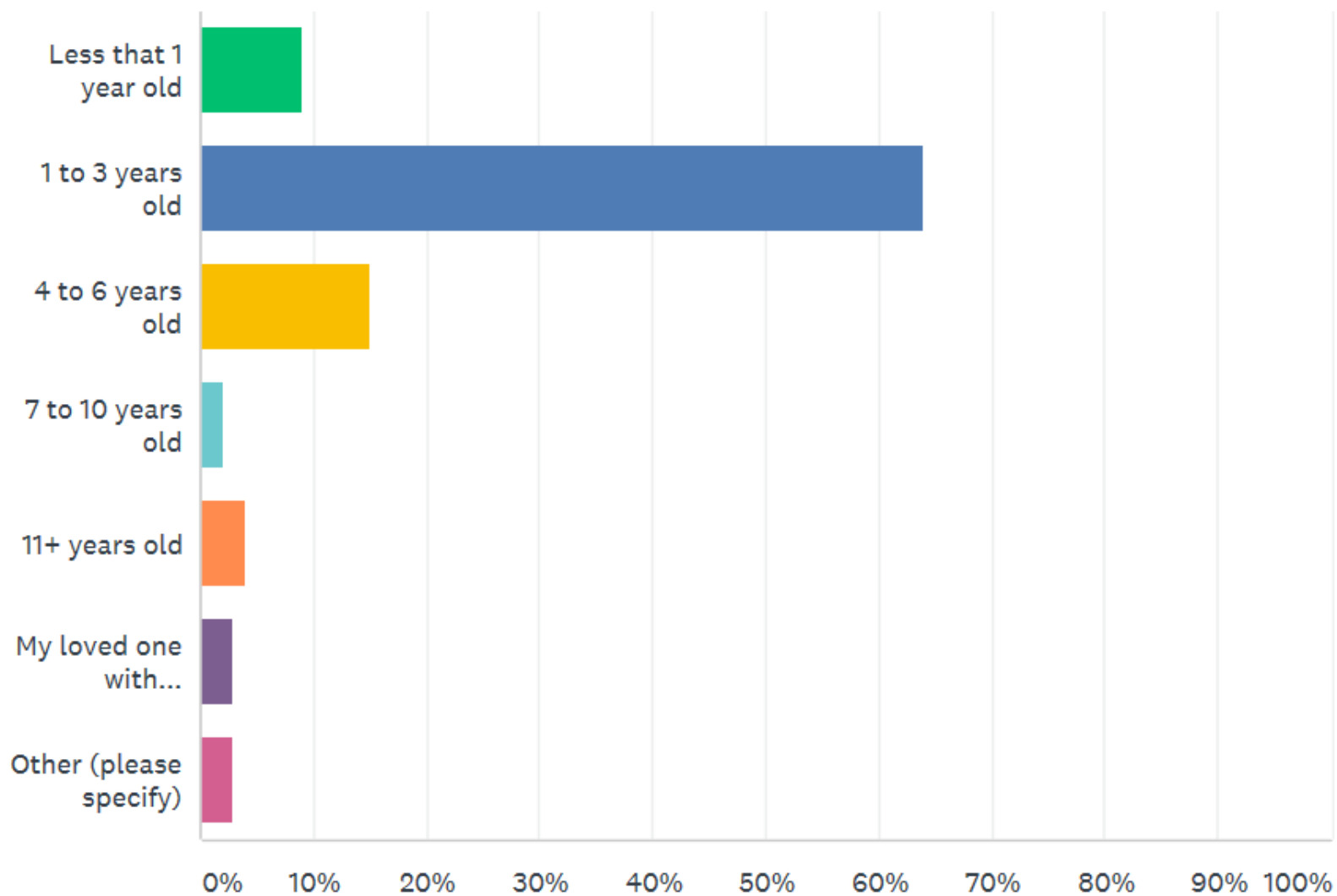
n=100

April 25, 2017 – September 22, 2017

Q1

At what age did your loved one with Dandy-Walker first go to the dentist?

Answered: 100 Skipped: 0



Q1. At what age did your loved one with Dandy-Walker first go to the dentist?

ANSWER CHOICES		RESPONSES	
▼ Less that 1 year old		9.00%	9
▼ 1 to 3 years old		64.00%	64
▼ 4 to 6 years old		15.00%	15
▼ 7 to 10 years old		2.00%	2
▼ 11+ years old		4.00%	4
▼ My loved one with Dandy-Walker has never been to the dentist		3.00%	3
▼ Other (please specify)	Responses	3.00%	3
TOTAL			100

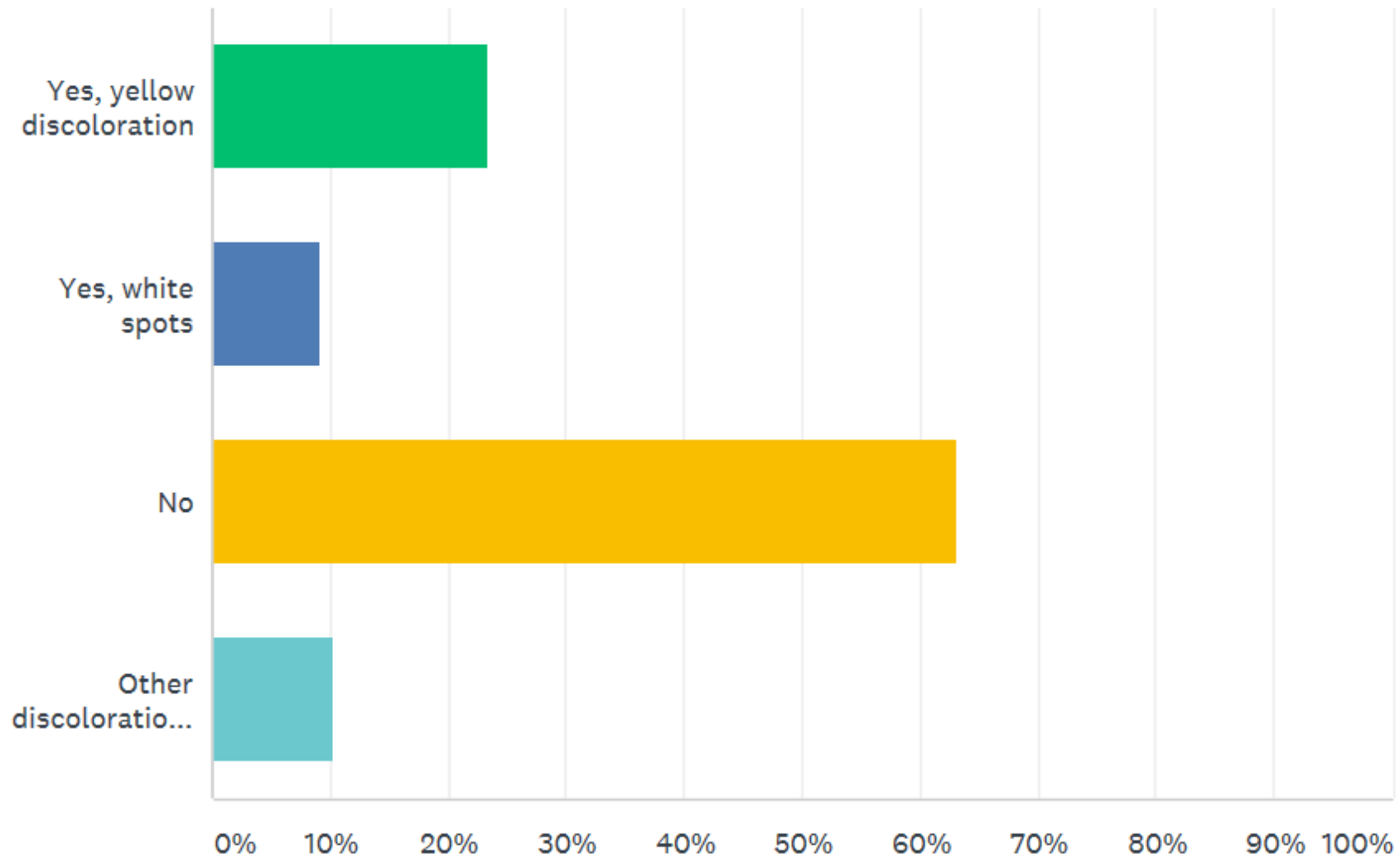
Q1. Comments

- She has not gone yet at 18 months.
- Scheduled to go next month at 4 1/2 years old.
- We have been taking him to the dentist since he was a baby. Now at 15, he's never had an exam or cleaning because he has not allowed them. Dentist didn't want to fully sedate him either.

Q2

Were or are any of your loved one's erupted teeth discolored?

Answered: 98 Skipped: 2



Q2. Were or are any of your loved one's erupted teeth discolored?

ANSWER CHOICES		RESPONSES	
▼ Yes, yellow discoloration		23.47%	23
▼ Yes, white spots		9.18%	9
▼ No		63.27%	62
▼ Other discoloration (please specify)	Responses	10.20%	10

Total Respondents: 98

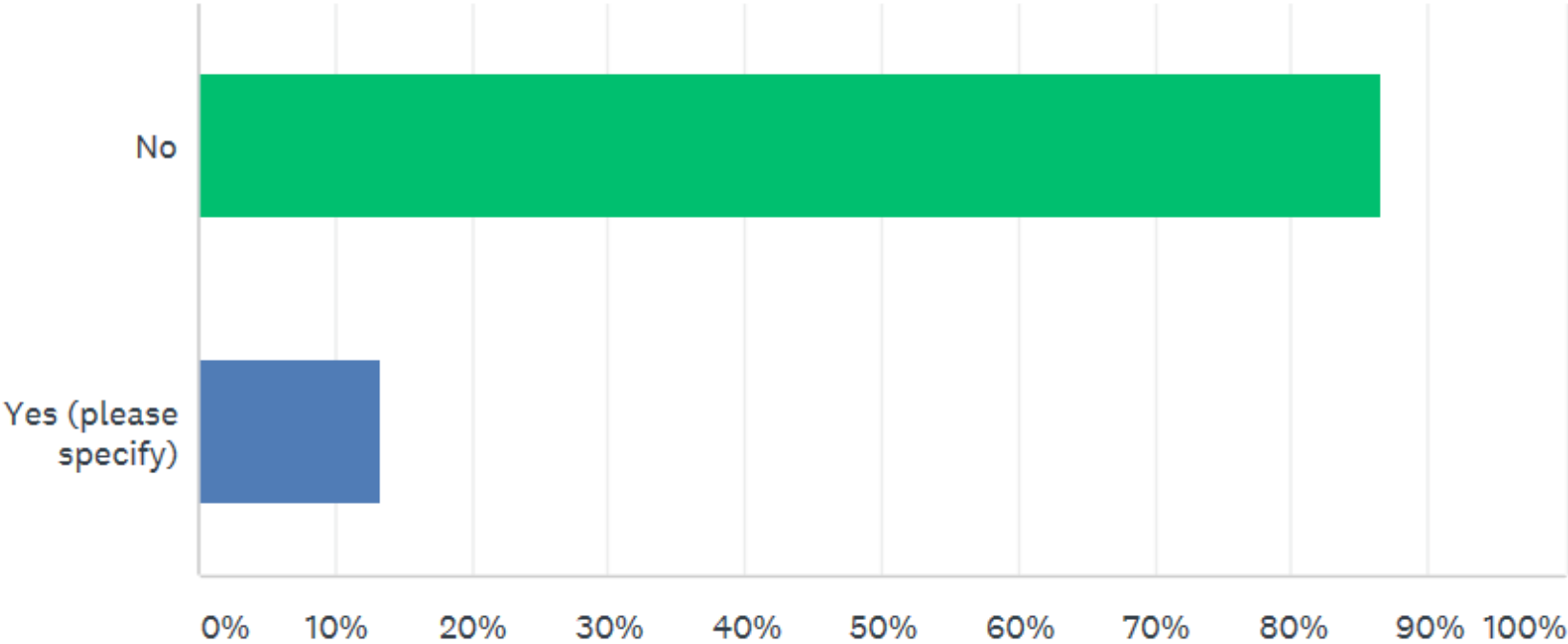
Q2. Comments

- Brown
- Baby teeth had a few white spots
- Hypo mineralization with row USB markings on back teeth
- At around age 2 had tooth that had "died" the tooth was gray in color
- Her teeth look normal at eruption but I have noticed that they build "sweaters" easily. We brush her teeth twice per day most days. She usually has "sweaters" when she wakes in the AM and by the afternoon.
- There were stains on his baby teeth due to the amount of medication when he was a baby. There are no stains on our sons teeth now, he is 13.
- Brown on top two front teeth
- Black from iron supplement
- Calcium deposits

Q3

Did the dentist provide any information on what to expect about future dentition?

Answered: 97 Skipped: 3



Q3. Did the dentist provide any information on what to expect about future dentition?

ANSWER CHOICES		RESPONSES	
▼ No		86.60%	84
▼ Yes (please specify)	Responses	13.40%	13
TOTAL			97

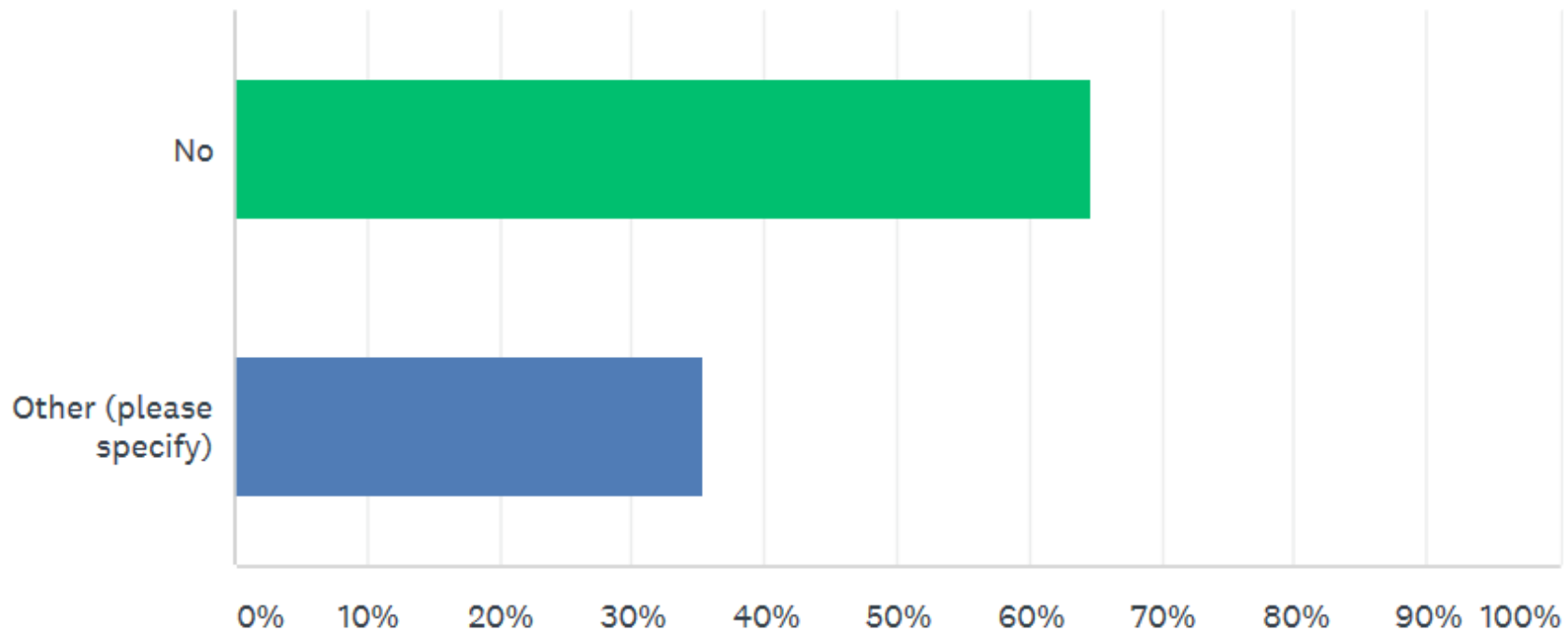
Q3. Comments

- G-J tube and NPO caused severe oral defensiveness. Plaque and tartar build-up is an issue. Some teeth are delayed in erupting.
- Information about losing teeth, how to floss, appropriate toothpaste
- As my son is developmentally delayed dentist said would need to be sedated for future visits also we talked about how to attempt to care for his teeth
- Just keep brushing and flossing
- Our son was adopted at age 7 and the Dentist said his white spots were probably from falling and the baby tooth hitting the adult teeth.
- Two teeth had not grown in - they are not present among baby teeth and likely not among adult, either.
- Just general dental education
- He has crooked teeth and needs braces but not recommended because he wouldn't be able to take care of them
- Risk of cavities because of the boost she drinks. Teeth cleaning every 6 months and maybe braces in the future
- Keep brushing twice a day. He has healthy gums, teeth.
- Providing routine care as typical patient
- Cleft lip and pallet

Q4

Did the dentist provide any information on what precautionary measures can be taken now to assure the most healthy dentition?

Answered: 96 Skipped: 4



Q4. Did the dentist provide any information on what precautionary measures can be taken now to assure the most healthy dentition?

ANSWER CHOICES	RESPONSES
▼ No	64.58% 62
▼ Other (please specify)	Responses 35.42% 34
TOTAL	96

Q4. Comments

- No milk bottles in bed
- As all dentist do, to brush regularly
- Brushing teeth regularly.
- Brush his mouth well with an open mouth
- General teeth brushing and flossing, cutting back on sugar
- Try to brush if she will allow
- Just the normal brushing, flossing and using a fluoride mouth wash
- Sugar free diet and steel caps on milk teeth
- Brush 3 times a day and 3 dental cleanings a year
- Flossing, fluoride free toothpaste until he learns to spit, regular cleanings
- Visits around every year or so. If he is being sedated for another test the doctors and dentist work together so he only needs to be sedated once.
- Yes, but it is the same as any other child.
- He suggested sealant because brushing is not well tolerated.

Q4. Comments (continued)

- Keep teeth brushed
- Keep brushing
- They have extracted some teeth to try and avoid braces.
- Brushing
- She recommended sealing molars
- Again, general education around brushing and flossing
- Always brush and avoid sugar
- Brush her teeth
- Our dentist understood the sensory issues that can be a barrier to basic dental care. Issues with a very sensitive gag reflex, aversion to toothbrush and toothpaste were handled patiently.
- Brushing and flossing regularly
- Brush regularly, do fluoride treatments
- Ensure he brushes his teeth all the time, which he does. He likes brushing his teeth.

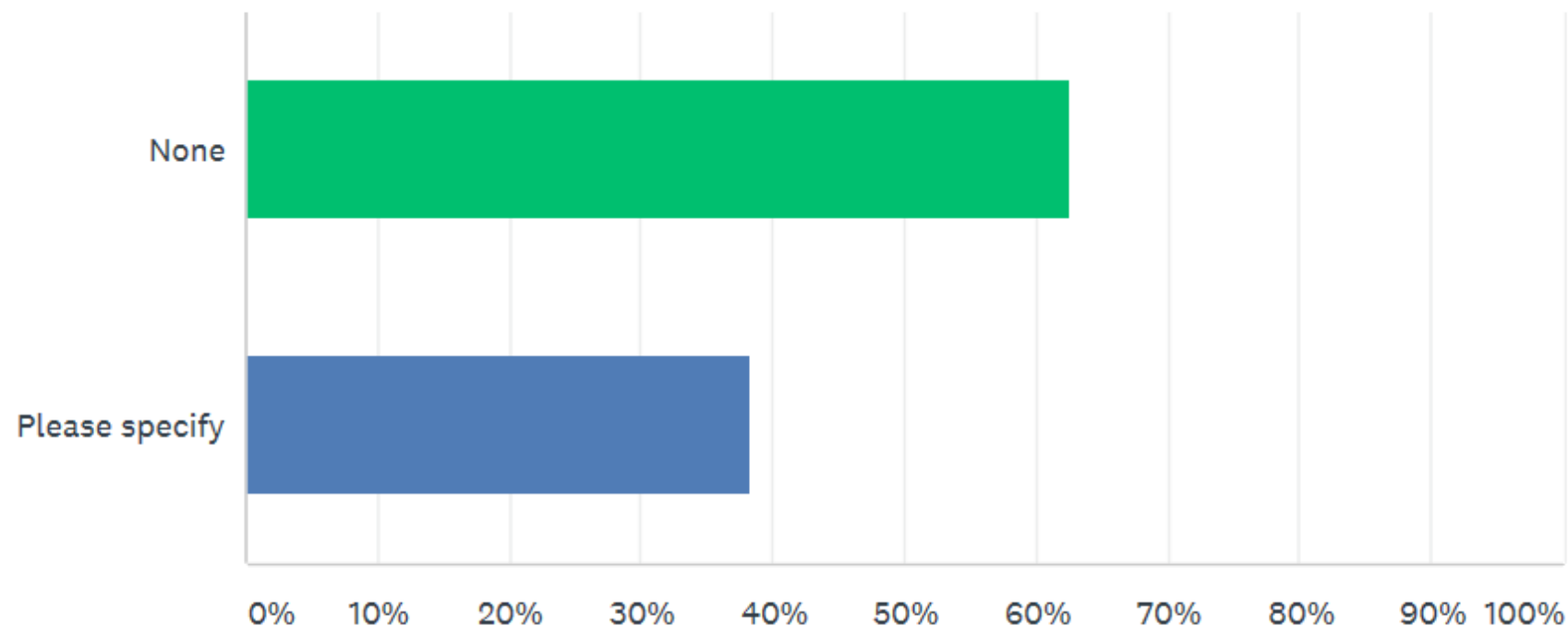
Q4. Comments (continued)

- The dentist sent him to the hospital to get some of his baby teeth out
- Brush teeth and rinse mouth a few times daily
- Keep brushing
- Typical dental care
- How to brush his cleft
- Standard dental care. We discussed antibiotics pre-treatment but he said that was not necessary even knowing her condition and having a shunt. He was knowledgeable about hydrocephalus after working at Shriners.
- Brush daily and only water after brushing at bed time
- She needs sedation for even x-rays

Q5

Did your loved one with Dandy-Walker have any other dental issues of significance you would like to note (e.g., extra teeth, missing adult teeth, etc.)?

Answered: 99 Skipped: 1



Q5. Did your loved one with Dandy-Walker have any other dental issues of significance you would like to note (e.g., extra teeth, missing adult teeth, etc.)?

ANSWER CHOICES	RESPONSES
▼ None	62.63% 62
▼ Please specify	Responses 38.38% 38
Total Respondents: 99	

Q5. Comments

- Teeth growing in behind other teeth
- Missing baby tooth. Never developed. Still has space there.
- Several fused teeth, jaw too small for all adult teeth
- Early eruption of teeth and early loss of baby teeth
- Jaw misalignment
- He has bruxism all day and night. At the age of 7, an ectopic tooth appeared in the roof of the mouth, he has 8 years old now.
- Molars haven't come all the way up
- Delayed eruption. Six years old. Some problems may not have manifested yet.
- Baby teeth slow and in wrong order coming in. Lip tie and large gap between front teeth.
- Extra tartar build up on back of baby teeth despite 2x/day cleaning
- Easily chipped. Spaced apart front teeth. Odd shaped.
- Tooth grinding at night
- Missing some adult teeth

Q5. Comments (continued)

- No teeth till after 1st birthday
- As stated above my son is developmentally delayed, he uses ruminating as a soothing mechanism which in turn has ruined most of his teeth, the remaining ones are capped to try to prevent further damage. He has lost many of his adult teeth due to this problem.
- Our son has had no dental problems, not even a cavity
- Missing one eye tooth, both baby and adult. Some baby teeth never fell out, dentist pulled them and it took almost a year for the adult tooth to come in.
- Missing baby tooth
- Missing 1 adult molar. Strong gum tissue she had 10 baby teeth has to be pulled she is 16 and still has baby teeth.
- After a head CT scan as an infant we were told he had "additional teeth." Yet, when he went to the dentist at age 5, he had not yet erupted at least one back molar and we were told it was most likely missing.
- One tooth came in backwards
- Weak teeth
- The eruption of teeth caused extreme oral and eating aversion
- Missing one tooth, no permanent tooth behind it.
- Had have some baby teeth pulled to make room for adult teeth

Q5. Comments (continued)

- A lot of cavities despite regular brushing. Recent frenectomy under top lip.
- Not at this time but only 7 years old
- Extra wisdom tooth
- His did not grow in the typical order. He needed an orthodontic type of spacer to hold the space for one tooth to come in. His wisdom teeth came in earlier than any of his 4 siblings including his twin. He had a cyst in the gum of one wisdom tooth and ended up with some complications with anesthesia.
- Extra wisdom tooth
- A few chipped teeth from bad falls due to vestibular dysfunction
- Small jaw, she may possibly have overcrowding and need braces.
- Extra teeth
- She got teeth pulled due to cavities
- His teeth came in late, had crowding in lower, 4 teeth extracted under sedation.
- He had cleft gums. He'll need braces in the future.
- Multiple root canals, cavity prone teeth
- Extra teeth

Thank you for all survey participants!

